

---

**| RESEARCH ARTICLE**

## **Various Clinical Manifestation of Omphalomesenteric Duct Remnant in a Child: A Case Report**

**Jonsinar Silalahi**

*MB MCh BA Paed. Department of Anatomy and Surgery, Faculty of Medicine Soegijapranata Catholic University, Semarang, Indonesia*

**Corresponding Author:** Jonsinar Silalahi, **E-mail:** [jonsinar@unika.ac.id](mailto:jonsinar@unika.ac.id)

---

**| ABSTRACT**

Omphalomesenteric duct (OMD) remnant is a condition in which the omphalomesenteric duct fails to obliterate completely or partially. Failure in this step can produce various patterns, such as a vitelline cyst, umbilical sinus, polyp, Meckel's diverticulum, and patent OMD. Various clinical manifestations of OMD rarely occur in one patient. We present the case of omphalomesenteric duct remnant, manifested as anterior wall abdominal mass, intraperitoneal hemorrhage, and obstructive ileus. Case report: A four-year-old girl was referred to our hospital with obstructive ileus and abdominal wall mass on the left lower quadrant. Contrast-enhanced abdominal computed tomography (CT) scan found an irregular cystic mass in the abdominal cavity that adheres to the anterior wall of the abdomen and bowel structure with a fluid-solid level without enhancement. Further medical history was taken and found a history of intermittent watery umbilical discharge that appears three times in 2 years after birth. Omphalomesenteric duct remnant was suspected, then proceed to exploratory laparotomy. We found intraperitoneal hemorrhage and 5x4 centimeters frail mass adhering to the anterior wall of the abdomen on the left side of the umbilicus. Histopathological examination confirmed intestinal tissue, suggesting remnants of the omphalomesenteric duct and pancreatic tissue with a chronic inflammatory pattern. Diagnosing omphalomesenteric duct remnant could be challenging and should be considered a differential diagnosis of obstructive ileus, particularly if persistent umbilical discharges are also present. On the other hand, early diagnosis and appropriate management of persistent umbilical discharge could prevent a greater outcome.

**| KEYWORDS**

Omphalomesenteric Duct Remnant, Intraperitoneal Bleeding, Obstructive Ileus.

**| ARTICLE INFORMATION**

**ACCEPTED:** 01 May 2024

**PUBLISHED:** 16 May 2024

**DOI:** 10.32996/jmhs.2024.5.2.8

---

### **1. Introduction**

Omphalomesenteric duct (OMD) remnant is a condition in which the omphalomesenteric duct fails to obliterate completely or partially (Muniraman, Sardesai, and Sardesai 2018). The fate of the omphalomesenteric duct should be obliterated in the ninth week of gestation, but failure on this step can produce various patterns such as vitelline cyst, umbilical sinus, polyp, Meckel's diverticulum, and patent OMD (Muniraman et al. 2018) (Azhar et al. 2021). Clinical presentations that occur frequently are gastrointestinal bleeding, intestinal obstruction, and umbilical abnormalities (Muniraman et al., 2018). Various clinical manifestations of OMD rarely occur in one patient (Muniraman et al., 2018). We present the case of omphalomesenteric duct remnant, manifested as anterior wall abdominal mass, intraperitoneal hemorrhage, and obstructive ileus.

### **2. Case Presentation**

A four-year-old girl, 16.5-kilogram weight, was referred to our hospital with obstructive ileus and an abdominal tumor on the left lower quadrant. A week prior, the parents noticed an abdominal mass on the left side and intermittent pain and nausea. They came to the primary care clinic and received anti-emetics, then referred to a surgeon appointment for the next day. The symptoms were dramatically reduced, and the parents delayed their outpatient appointment. She came to the emergency department four days

later with obstipation and vomiting. Physical examination found fever (38.0°C), slight tachycardia (110 bpm) and palpable mass in the left lower quadrant with decreased bowel sound. Laboratory study results were anemia (8.4 gr/dL) and thrombocytopenia (86.000/mm<sup>3</sup>), with a normal count of leucocytes (9.110/ mm<sup>3</sup>). A nasogastric tube was placed and produced feces, indicating obstructive ileus. A serial complete blood count was obtained prior to surgery, then found decreased hemoglobin to 5.4 gr/dL. Contrast-enhanced abdominal computed tomography (CT) scan found an irregular cystic mass of 5.5x4.6x5 cm in size in the abdominal cavity that adheres to the anterior wall of the abdomen and bowel structure with a fluid-solid level without enhancement, also partial ileus. Further medical history was taken and found a history of intermittent watery umbilical discharge that appears three times in 2 years after birth, accompanied by fever that was reduced with antipyretic. No abdominal blunt trauma was reported within two weeks prior. Omphalomesenteric duct remnant was suspected.

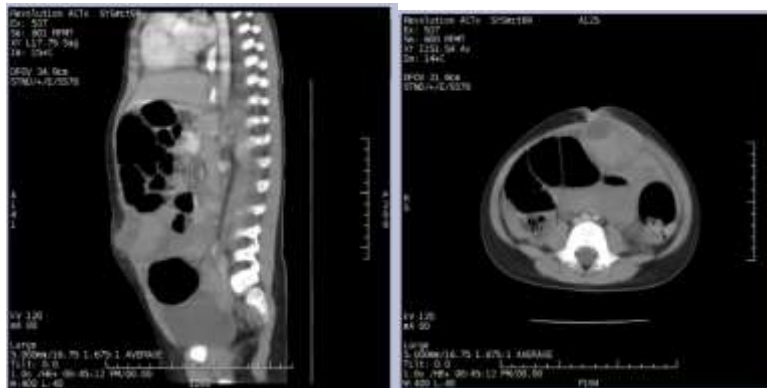


Figure 1 Coronal and axial contrast-enhanced abdominal CT scan shows an irregular cystic mass of 5.5x4.6x5 cm size in the abdominal cavity that adheres to the anterior wall of the abdomen and bowel structure with a fluid-solid level without enhancement, also partial ileus

Exploratory laparotomy was performed the next day after 170 milliliters packed red cell transfusion was done. We found intraperitoneal hemorrhage of approximately 300 milliliters and found 5x4 centimeters frail mass adhering to the anterior wall of the abdomen on the left side of the umbilicus without a clear connection to the umbilicus and bowel, also mild adhesion in the major omentum. The mass was then resected with a margin-free zone obtained, and adhesiolysis was performed. Controlled hemostasis was achieved, and then an exploration of the four-quadrant was proceeded. Another mass was not found in our exploration. The specimen was then collected and sent for pathologic examination. Histopathological examination confirmed intestinal tissue, suggesting remnants of the omphalomesenteric duct and pancreatic tissue with a chronic inflammatory pattern.

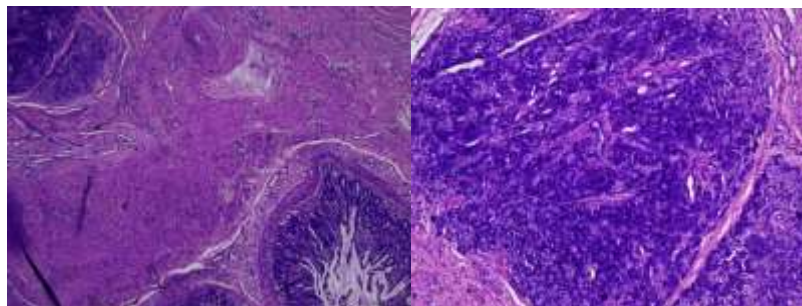


Figure 3 Hematoxylin-eosin stain in 40x magnification (left) and 100x magnification (right) found intestinal tissue and pancreatic tissue with chronic inflammatory pattern.

The patient was then admitted to the pediatric intensive care unit after laparotomy for two days and then moved to the regular ward after her condition was stable. The patient was discharged after five days of hospitalization. A week after discharge, the patient came to the pediatric surgery outpatient clinic for follow-up, not complaining of any symptoms and remaining well.

### 3. Discussion

The omphalomesenteric duct is a structure that is developed to connect the yolk sac and the intracoelomic portion, which will be derived to the alimentary canal (Agrawal and Memon 2010). Failed obliteration between the 5th to 7th weeks of gestation could lead to patency of this structure, depending on levels of patency (Giacalone et al. 2004). The fate of the omphalomesenteric duct remnant could become a vitelline cyst, umbilical sinus, polyp, Meckel's diverticulum, and patent OMD (Muniraman et al. 2018) (Azhar et al. 2021). Cutaneous manifestation of OMD remnant is also recorded in some cases as umbilical mass (Solomon-Cohen

et al. 2019). Meckel's diverticulum is the most common finding associated with OMD remnant, assigning 2–3% of gastrointestinal anomalies in children. Meanwhile, findings of completely patent OMD are approximately 0.0063–0.067% (Agrawal and Memon 2010). Clinical presentation of OMD remnant may vary from intestinal obstruction, abdominal pain, umbilical anomalies, and rectal bleeding (Azhar et al. 2021). However, simultaneous clinical presentations are rarely reported (Muniraman et al., 2018).

Radiology imaging frequently used to confirm the diagnosis are contrast-enhanced CT scans, Technetium-99m (Tc99m)-pertechnetate scintigraphy, as known as Meckel's scan, and abdominal sonography (Bagade and Khanna 2015). Surgical management may vary based on the patient's condition, but minimally invasive surgeries are more favorable (Kang et al., 2021). Histopathology findings were diverse; frequently, a full lining of a small intestinal type, identical to that of the adjacent bowel; however, gastric, duodenal, colonic mucosa or pancreatic tissue may also be found (Park et al. 2014). The mortality of OMD is rather low, as only four patients reported died in the 21st century in developing countries. Causes of mortality are sepsis, peritonitis, intussusception, peptic ulcer hemorrhage, as well as other postsurgical complications (Solomon-Cohen et al. 2019).

We reported simultaneous clinical presentations of OMD that happened in a patient with a long history of intermittent umbilical discharge accompanied by fever. We suspected the OMD was infected at that time, but then partially resolved and became a chronic inflammation that led to a cyst and inflammatory mass. Thus, the mass became larger, causing obstructive ileus. The heterotopic pancreas is also present in our findings. We suspected the origin of intraperitoneal bleeding either from the heterotopic pancreas or the nature of OMD, as there is no abdominal blunt trauma was recorded.

#### **4. Conclusion**

This study aimed to present a case of an omphalomesenteric duct (OMD) remnant with multiple clinical manifestations, including an anterior wall abdominal mass, intraperitoneal hemorrhage, and obstructive ileus. The patient, a four-year-old girl, presented with symptoms of obstructive ileus and an abdominal mass, initially managed with anti-emetics but later required emergency intervention due to worsening symptoms. Radiological findings revealed an irregular cystic mass adhering to the anterior abdominal wall, which, upon laparotomy, was confirmed to be a remnant of the omphalomesenteric duct with associated inflammatory changes and heterotopic pancreatic tissue. The study discusses the embryological basis of OMD, its various clinical presentations, diagnostic modalities, and surgical management options. Limitations include the rarity of simultaneous clinical presentations and the possibility of missed diagnoses due to varied clinical manifestations. Future research should focus on larger case series to better understand the pathophysiology, diagnostic approaches, and optimal management strategies for OMD remnants, especially those with complex clinical presentations. Additionally, investigating the long-term outcomes and potential complications of OMD remnants could provide valuable insights into patient care and prognosis.

**Conflict of Interest:** The authors declared that they have no conflict of interest.

**Ethical approval:** Ethical clearance is not required because the patient is a managed patient who has agreed to undergo surgery based on informed consent. Furthermore, the patient's family has also agreed to publication for the benefit of scientific development.

**Informed consent:** The informed consent is included in the hospital's informed consent procedure when the patient is admitted, and the patient or family has agreed to the procedure.

#### **References**

- [1] Agrawal, S, and Ameen, M. (2010). Patent Vitellointestinal Duct. *BMJ Case Report*. Doi: <https://doi.org/10.1136/bcr.12.2009.2594>.
- [2] Azhar, M, Naima Z, Syed R. T, and Mishraz S. (2021). Spectrum of Omphalomesenteric Duct Related Anomalies and Their Surgical Management in Children. *Cureus* 13(3):e13898. doi: <https://doi.org/10.7759%2Fcureus.13898>.
- [3] Bagade, S, and Geetika K. (2015). Imaging of Omphalomesenteric Duct Remnants and Related Pathologies in Children. *Current Problems in Diagnostic Radiology* 44(3):246–55. doi: <https://doi.org/10.1067/j.cpradiol.2014.12.003>.
- [4] Giacalone, G., Vanrykel J. P., Belva F., Aelvoet C., De Weer F., and Val E S. (2004). Surgical Treatment of Patent Omphalomesenteric Duct Presenting as Faecal Umbilical Discharge. *Acta Chirurgica Belgica* 104(2). doi <https://doi.org/10.1080/00015458.2004.11679538>.
- [5] Kang, A, Soo-Hong K, Yong-Hoon C, and Hae-Young K. (2021). Surgical Perspectives of Symptomatic Omphalomesenteric Duct Remnants: Differences Between Infancy and Beyond. *World Journal of Clinical Cases* 9(36):11228–36. doi <https://doi.org/10.12998%2Fwjcc.v9.i36.11228>.
- [6] Muniraman, H, Tara S, and Smeeta S. (2018). Disorders of the Umbilical Cord. *Pediatrics in Review* 39(7):332–41. doi: <https://doi.org/10.1542/pir.2017-0202>.
- [7] Park, E, Hyojin K, Kyu W J, and Jin-Haeng C. (2014). Heterotopic Pancreas in Omphalomesenteric Duct Remnant Results in Persistent Umbilical Discharge. *The Korean Journal of Pathology* 48(4):323–26. doi: <https://doi.org/10.4132%2FKoreanJPathol.2014.48.4.323>.
- [8] Solomon-Cohen, E, Moshe L, Igor S, Dan B, Omri Z, Rivka F, Michael M, Daniel M, Yael A L, Emmilia H, and Assi L. (2019). 'Cutaneous Presentations of Omphalomesenteric Duct Remnant: A Systematic Review of the Literature'. *Journal of the American Academy of Dermatology* 81(5):1120–26. doi <https://doi.org/10.1016/j.jaad.2019.02.033>.