

eISSN 2615-496X

*July 2023*

Juli 2023

# Indonesian Journal of Obstetrics & Gynecology Science

# O( )GYNIA



Volume 6 Number  
Volume 6 Nomor

# 2

# OBGYNIA

Indonesian Journal of Obstetrics & Gynecology Science

## Susunan Redaksi

### Penanggung Jawab

Kepala KSM/Dep Obstetri & Ginekologi  
RSUP Dr. Hasan Sadikin Bandung

### Pemimpin Redaksi

Adhi Pribadi

### Wakil Pemimpin Redaksi

Windi Nurdiawan

### Editor

Sofie Rifayani Krisnadi

Herman Susanto

Hartanto Bayuaji

Anita Rachmawati

Edwin Armawan

Kemala Isnainiasih Mantilidewi

Bobby Indra Utama

### Copyeditors

Kasno Pamungkas

Nani Darmayanti

### Administrasi dan Keuangan

Hanom Husni Syam

### Sekretariat

Asep Rahman

Indrianti

### Alamat Redaksi

Dept/KSM Obstetri dan Ginekologi Fakultas Kedokteran Universitas Padjadjaran/

RSUP. Dr. Hasan Sadikin

Jl. Pasteur No.38 Bandung

Telepon: 022-2032530; Fax:022-2039086

*E-mail:* obgyniajurnal@gmail.com; *website:* www.obgynia.com

Indonesian Journal of Obstetrics & Gynecology Science (Obgynia) is accredited (2018-2022) by National Journal Accreditation (ARJUNA) Managed by Ministry of Research, Technology, and Higher Education, Republic of Indonesia with Third Grade (Peringkat 3, Sinta 3), No 158/E/KPT/2021

Diterbitkan oleh:

Dept/KSM Obstetri dan Ginekologi Fakultas Kedokteran Universitas Padjadjaran/

RSUP. Dr. Hasan Sadikin



Terbit Setiap 4 Bulan (Maret, Juli, dan November)

## Editorial

- Manajemen Jangka Panjang Endometriosis: Dapatkah Progestin Menjadi Andalan?  
**Hartanto Bayuaji** 155

## Artikel Review

- Efektivitas Penerapan Bundles IDO Sectio Caesarea: Scoping Review  
**Siti Jubaedah, Yanti Hermayanti, Ermiami** 162
- Effect of Curcumin towards Metabolic Disturbance Parameters in Patient with PCOS: A Systematic Review and Meta-Analysis of Clinical and Preclinical Randomized Controlled Trials  
**Angeline Ekafentie, Nicolas Daniel Widjanarko, Yuliana Yosephine, Mutiara Riani** 170

## Research Artikel

- Perbandingan Faktor Risiko antara Pertumbuhan Janin Terhambat Onset Dini dan Lambat di RSUD Dr. Moewardi  
**Prilla Firsty Prasetyo Putri, Muhammad Adrianes Bachnas, Nutria Widya Purna Anggraini, Abdurahman Laqif** 185
- Hubungan Ekspresi Cyclooxygenase-2 (Cox-2) dengan Invasi Limfovaskuler, Infiltrasi Sel Radang dan Stadium Kanker Serviks  
**Andi Ahmed Onterio, Syahrul Rauf, Nugraha Utama Pelupessy, Rina Masadah, Isharyah Sunarno, Nasrudin Andi Mappaware, Sharvianty Arifuddin** 194
- Correlation of Leucine-Rich- $\alpha$ -2-Glycoprotein- 1 (LRG-1) Level in Urine with Cervical Cancer Stage, Histology Type and Histology Grading  
**Prilly Astari, Syahrul Rauf, Elizabet C. Jusuf, Maisuri T. Chalid, Sharvianty Arifuddin, Retno B. Farid** 203
- The Relationship between Ferritin Levels and Uterine Inertia in Labor Women  
**Astri Ayu Agus, Andi Mardiah Tahir, Nurbani Bangsawan, Maisuri T. Chalid, Efendi Lukas, Lenny M. Lisal** 212
- The Correlation Between CYP19 Levels, VAS of Dysmenorrhea, and the Grading Score ASRM of Endometriosis  
**Muhammad Komarul Hakim, Fatimah Usman, Heriyadi Manan, Mgs. Irsan Saleh** 220
- Hubungan antara Kisspeptin-10 dan Preeklamsia Berat  
**Dwi Arry Wibowo, Nusratuddin Abdullah, Isharyah Sunarno, Andi Nursanty Padjalangi, Upik A. Miskad** 227
- Effect of Corona Virus Disease 2019 (Covid-19) on the Incidence of Preterm Birth and Asphyxia At Banjar Regional General Hospital  
**Kulfa Sholehah, Akhmad Yogi Pramatirta, Firman F. Wirakusumah** 236
- Prevalensi dan Luaran Pasien dengan Spektrum Plasenta Akreta  
**Adiguna Gurnita, Setyorini Irianti** 247
- CA-125 Prediktor Sitoreduksi pada Pasien Kanker Ovarium Tipe Epitel  
**Bagja Dumas Darwizar, Gatot Nyarumenteng Adipurnawan Winarno, Jusuf Sulaeman Effendi** 255

Karakteristik Karsinoma Ovarium Pra-Menopause dengan Kadar CA 125 $\leq$ 200 U/mL di RSUP Dr. Hasan Sadikin Bandung dari Tahun 2019–2021	263
<b>Yudi Mulyana Hidayat, Eunike Febe Febriani, Ali Budi Harsono, Gatot N.A. Winarno, Andi Kurniadi</b>	
Peran Phosphatase Regenerating Liver-3 dan Vascular Endothelial Growth Factor dalam Progresivitas Kanker Ovarium Epitelial	271
<b>Sharvianty Arifuddin</b>	
Perbandingan Kadar Reactive Oxygen Species (Ros) sebagai Penanda Stres Oksidatif pada Ibu Hamil Dengan dan Tanpa Vaginosis Bakterial	281
<b>Dwicky Limbersia Aries, Maisuri T. Chalid, Rina Previana Amiruddin, Rizalinda Sjahril, Efendi Lukas, Susiawaty Mustafa</b>	
Hubungan Antara Indeks Massa Tubuh dan Paritas dengan Inkontinensia Urin Tipe Tekanan dan Desakan pada Lansia	288
<b>Farahdiba Aisyah Putri Ridwan, Amir Fauzi, Sadakata Sinulingga, Hadrians Kesuma Putra, Ridwan Abdullah Putra</b>	
COVID-19 Infection in Pregnancy Increases Length of Hospitalization and Need for Postpartum Intermediate Care	296
<b>Slamet Susanto, Zulvayanti, Windi Nurdiawan, Djamhoer Martaadisoebrata, Hadi Susiarno</b>	
<b>Case Report</b>	
Achondroplasia Berulang pada Orangtua dengan Perawakan Normal: Laporan Kasus	306
<b>Fatima Zahra, Adhi Pribadi</b>	
Successful Repair Management for Urinary Bladder Perforation During Myomectomy on Cervical Myoma on Patients with Previous Cesarean Section: A Challenging Case Report	313
<b>Indra Adi Susianto, Ferry Santoso, Iwan Prasetyo, Diana Novitasari, Dimas Sindhu Wibisono, Jerry Ferdinand Saragih</b>	

## Pedoman bagi Penulis *Instruction for Author*

Indonesian Journal of Obstetrics & Gynecology Science (OBYNIA) adalah jurnal dalam bidang ilmu Obstetri & Ginekologi yang diterbitkan resmi oleh Departemen Obstetri & Ginekologi Fakultas Kedokteran Universitas Padjadjaran. OBYNIA menerbitkan artikel penelitian tentang kemajuan ilmiah, manajemen klinis pasien, teknik bedah, kemajuan pengobatan dan evaluasi pelayanan, manajemen serta pengobatan dalam bidang obstetri & ginekologi.

Pedoman bagi penulis yang akan menyerahkan naskah ke redaksi OBYNIA adalah sebagai berikut:

1. Naskah yang ditulis berkaitan dengan bidang ilmu Obstetri & Ginekologi
2. Naskah merupakan artikel asli (belum pernah dipublikasikan di tempat lain) yang bersumber dari hasil kajian atau penelitian.
3. Naskah ditulis dalam bahasa Indonesia atau Inggris.
4. Naskah disertai abstrak dalam bahasa Indonesia dan Inggris.
5. Naskah disertai kata kunci (*keywords*) dalam bahasa Indonesia dan Inggris.
6. Pengiriman naskah disertai biodata penulis, seperti nama lengkap, bidang kepakaran, alamat instansi (afiliasi), dan alamat surat elektronik (*email*).
7. Naskah dikirim secara *online submission* ke web [www.obgynia.com](http://www.obgynia.com). Apabila terdapat kesulitan dapat melalui email: [obgyniajurnal@gmail.com](mailto:obgyniajurnal@gmail.com)
8. Naskah yang masuk akan diseleksi oleh dewan redaksi. Jika dianggap perlu, naskah akan disunting melalui konsultasi dengan penulisnya.

### Format dan Sistematika

Naskah dikirim ke redaksi jurnal dalam bentuk softcopy (MS Word). Ukuran kertas A4 dengan jarak tepi atas 4 cm, tepi kiri dan bawah 3 cm,

serta tepi kanan 2 cm. Tebal naskah minimal 8 halaman dan maksimal 20 halaman. Penulisan naskah disusun dengan jarak spasi 2, format satu kolom, ditulis dengan sistematika penulisan sebagai berikut:

1. Judul (Times New Roman 14). Judul harus spesifik, jelas, ringkas, informatif, menggambarkan substansi atau isi dari tulisan, dan dapat menggugah rasa untuk membaca. Judul tidak perlu diawali dengan kata penelitian/ analisis/studi, kecuali kata tersebut merupakan pokok bahasan.
2. Nama Penulis (Times New Roman 12). Penulis harus menggunakan nama asli (bukan nama samaran) dan tidak mencantumkan gelar kesarjanaannya. Nama lengkap yang diikuti dengan gelar serta keterangan penulis dapat ditampilkan dalam *footnote*. Jika penulis lebih dari satu, harus dipisahkan dengan tanda koma (,).
3. Afiliasi Penulis (Times New Roman 12). Afiliasi merupakan alamat instansi/lembaga tempat penulis bekerja/berkarya/studi. Afiliasi ini berkaitan erat dengan kompetensi, tanggung jawab, dan konsekuensi yuridis yang diemban oleh lembaga asal penulis.
4. Korespondensi (Times New Roman 10). Korespondensi berisi alamat surat elektronik (*email*) penulis pertama.
5. Abstract dan Abstrak (Times New Roman 10). Isi *abstract* atau abstrak (Times New Roman 10). Abstrak terdiri atas: Tujuan (*Objective*), Metode (*Methods*), Hasil (*Result*), Kesimpulan (*Conclusion*), dan Kata Kunci (*Key words*). Tanpa singkatan/akronim, dan tanpa *footnote*. Abstrak ditulis bukan dalam bentuk matematis, pertanyaan, dan dugaan. Abstrak bukan merupakan hasil *copy paste* dari kalimat yang ada dalam naskah. Isi abstrak paling banyak memuat 200 kata.
6. Kata kunci/**Key words** (Times New Roman 10) Jumlah *keywords* maksimal lima kata

- kunci.
7. Pendahuluan (Times New Roman 12). Isi pendahuluan ditulis dengan font Times New Roman 12.
  8. Metode (Times New Roman 12). Isi metode kajian adalah desain, tata cara penelitian, teknik pengumpulan data, sumber data, cara analisis data, dan uji statistik. Jika menggunakan reagent Laboratorium, produsen dan nomor batch harap dicantumkan. Ditulis dengan font Times New Roman 12.
  9. Hasil (Times New Roman 12). Isi hasil dan pembahasan ditulis dengan font Times New Roman 12. Hasil bukan merupakan data mentah, melainkan data yang sudah diolah/dianalisis dengan metode yang telah ditetapkan. Apabila terdapat tabel dan gambar total maksimal 7 buah. Tabel dan gambar disertai nomor, keterangan dan analisis mengenai tabel dan gambar.
  10. Diskusi (Times New Roman 12) berisi pembahasan hasil penelitian, dan tidak mengulang pembahasan tabel
  11. Pembahasan (Times New Roman 12) merupakan jawaban terhadap tujuan penelitian.
  12. Conflict Of Interest (Times New Roman 12) Apabila penelitian disponsori oleh pihak yang berkepentingan dan kemungkinan berpengaruh terhadap hasil penelitian, mohon dicantumkan pernyataan.
  13. Saran (Times New Roman 12, jika ada). Saran sebaiknya ditulis dalam satu paragraf.
  14. Ucapan Terima Kasih (Times New Roman 12, jika ada), ditulis dalam satu paragraf.
  15. Daftar Pustaka (Times New Roman 12). Daftar pustaka merupakan sumber acuan/rujukan yang dijadikan bahan kutipan penulisan naskah. Penulisan daftar pustaka menggunakan aturan Vancouver. Jumlah sumber rujukan yang dijadikan daftar pustaka naskah maksimal 25 judul literatur ilmiah (80% literatur primer, seperti jurnal ilmiah, makalah ilmiah/prosiding, laporan penelitian, skripsi/tesis/disertasi; dan 20% literatur sekunder, seperti buku dan blog/web ilmiah internet). Ditulis dengan font Times New Roman 12.

## 16. Penulisan Tabel

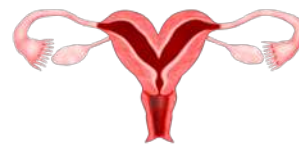Judul Tabel (Times New Roman 12)

Isi Tabel (Times New Roman 11)

Persalinan	N	%
Persalinan Preterm	1.255	38,54
Persalinan Aterm	2.001	61,46
Total	3.256	100

\*Keterangan Tabel (Times New Roman 9)

17. Penulisan Gambar Apabila teks naskah berisi gambar maka penulis harus mengirim file gambar aslinya dalam format JPEG atau PNG (600 dpi)



Gambar ( Times New Roman 12)

18. Penulisan Daftar Pustaka atau Rujukan

Daftar pustaka adalah semua sumber bahan bacaan atau literatur yang dijadikan kutipan penulisan naskah. Penulisan dan penyusunan daftar pustaka naskah Jurnal Obgynia menggunakan aturan *Vancouver*.

### Alamat Redaksi

KSM/Dept Obstetri dan Ginekologi Fakultas  
Kedokteran Universitas Padjadjaran/  
RSUP. Dr. Hasan Sadikin  
Jl. Pasteur No.38 Bandung  
Telepon: 022-2032530; Fax:022-2039086  
E-mail:obgyniajurnal@gmail.com;  
website: www.obgynia.com



9 772615 496004

## Successful Repair Management for Urinary Bladder Perforation During Myomectomy on Cervical Myoma on Patients with Previous Cesarean Section: A Challenging Case Report

Indra Adi Susianto,<sup>1,2</sup> Ferry Santoso,<sup>2</sup> Iwan Prasetyo,<sup>1,3</sup> Diana Novitasari,<sup>4</sup>  
Dimas Sindhu Wibisono,<sup>5</sup> Jerry Ferdinand Saragih<sup>6</sup>

<sup>1</sup>Department of Obstetrics and Gynecology Rumah Sakit Ibu dan Anak Anugerah Semarang,

<sup>2</sup>Department of Obstetrics and Gynecology Medical Faculty Soegijapranata Catholic

University Semarang, <sup>3</sup>Department of Obstetrics and Gynecology Rumah Sakit RAA

Soewondo Pati, <sup>4</sup>Department of Internal Medicine Rumah Sakit Santa Elisabeth Semarang,

<sup>5</sup>Department of Urologic Surgery Rumah Sakit Santa Elisabeth Semarang, <sup>6</sup>Department of

Anesthesia Rumah Sakit Santa Elisabeth Semarang

Correspondence: Indra Adi Susianto, Email: indraadisusianto@unika.ac.id

### Abstract

The 20-25% incidence of uterine myoma often experienced by women in childbearing age and 2% of these uterine myomas attach and grow in the uterine cervical area. The chief complain of cervical myoma are lumps in the lower abdomen that are getting bigger and pressing on the urinary bladder cause difficulty in urinating and are accompanied by bloody urine, although the amount of menstrual blood is still within reasonable limits. Like uterine myomas, cervical myomas are not fused with the myometrial lining but are covered by thin connective tissue on the surface. The procedure of cervical myoma based on ACOG (American College of Obstetrics and Gynecology) is hysterectomy if the patient no longer wants to get pregnant, or myomectomy if the patient still wants to have children. Both of these actions have a very high risk in which vascularization in the pelvic area will be very complex, pressure on cervical myoma will have a high risk of injuring the urinary bladder mucosa and when setting aside the lower segment of the uterus there is a risk of injury. We present a 38-year-old woman with 30 x 26 x 22 cm giant cervical myoma and secondary infertility that was treated with challenging laparotomi myomectomy in collaboration with urologist to preserve fertility. There was a tear in the upper part of the urinary bladder which was elongated with irregular edges measuring 12 x 5 cm after enucleation cervical myoma. The tear was repaired immediately and there are no complications in the form of vesico-vaginal fistulas or vesico-cervical postoperatively

**Key words :** Bladder Perforation, Myomectomy, Cervical Myoma, Secondary Infertility

## Penanganan Komplikasi Perforasi Vesika Urinaria saat Tindakan Miomektomi pada Mioma Servikal pada Pasien Bekas Seksio Sesaria: Sebuah Laporan Kasus

### Abstrak

20-25% insiden neoplasma jinak ini sering dialami oleh wanita terjadi pada wanita usia subur dan 2% nya melekat dan tumbuh pada area servik uteri. Meskipun jumlah darah menstruasi masih dalam batas wajar, tapi keluhan dari mioma uteri yang melekat pada servik adalah benjolan pada perut bawah yang semakin membesar dan menekan pada vesika urinaria sehingga menyebabkan kesulitan berkemih. Menurut American Collage of Obstetric and Gynecology tindakan miomektomi merupakan pilihan apabila pasien masih ingin mempunyai keturunan. Meskipun resiko yang sangat tinggi karena vaskularisasi area pelvis sangat kompleks, tindakan ini juga beresiko mencederai mukosa vesika urinaria dan resiko cedera pada ureter tunnel. Tulisan ini merupakan kasus seorang wanita berusia 38 tahun dengan mioma servikal permagna berukuran 30 x 26 x 22 cm dengan infertilitas sekunder yang dilakukan miomektomi secara laparotomi bersama ahli urologi. Terdapat perforasi pada vesica urinaria bagian atas memanjang dengan tepi tidak beraturan berukuran 12 x 5 cm setelah tindakan enukleasi mioma serviks. Robekan tersebut dapat diperbaiki dan tidak ada komplikasi berupa fistula vesiko- vagina atau vesiko-serviks pasca operasi.

**Kata kunci:** Perforasi Kandung Kemih, Miomektomi, Mioma Serviks, Infertilitas Sekunder



## Introduction

Myoma Uteri or Leiomyoma Uteri or Fibromioma uteri is a benign tumor that grows from the smooth muscle of the uterus and consists of cells of smooth muscle tissue, connective tissue and collagen. The incidence of benign neoplasms is the most common and often experienced by women in childbearing age and 2% of these uterine myomas attach and grow in the uterine cervical area. The growth of myomas is generally influenced by excessive levels of the estrogen hormone; this causes a higher incidence of myomas to occur in women in childbearing age.<sup>1-3</sup>

In the FIGO (Federation International Gynecology Organization) classification, the growth of uterine myomas is divided based on where they grow; intramural myomas are myomas that grow into the uterus. The subserosal myomas and submucosal myomas type is when the myoma grow either inside or outside the uterus. Then, myomas that come out of the uterus are pedunculated myomas; while myomas attached to the broad ligament are intraligamentary myomas, and myomas that originate from the cervix and grow into the pelvic cavity are cervical myomas. Pressure from cervical myomas is very difficult to detect, which is the reason why an MRI (magnetic resonance imaging) is needed to make it more accurate.<sup>2,4</sup>

Complaints from those who suffer from uterine myomas attached to the cervix are lumps in the lower abdomen that are getting bigger and pressing on the urinary bladder cause difficulty in urinating and are accompanied by bloody urine, although the amount of menstrual blood is still within reasonable limits. Like uterine myomas, cervical myomas are not fused with the myometrial lining but are covered by thin connective tissue on the surface. The number of cervical myomas cases that cause pressure to the urinary bladder and cause urinary

disturbances is very rare, it is around 0.04-1.5% of the total cases of cervical myomas, but the number of cases of cervical myomas at reproductive age occurs 1: 3 of all cervical myomas at all ages. Some literature writes that 49% of patients with cervical myoma pressure towards the vesica urinary causes urinary incontinence, dysuria, dribbling, and 11% is accompanied by hematuria.

The procedure of cervical myoma based on ACOG (American College of Obstetrics and Gynecology) is hysterectomy if the patient no longer wants to get pregnant, or myomectomy if the patient still wants to have children. Both of these actions have a very high risk in which vascularization in the pelvic area will be very complex, pressure on cervical myoma will have a high risk of injuring the urinary bladder mucosa and when setting aside the lower segment of the uterus there is a risk of injury.<sup>6,7</sup>

## The Case Report

A 38-year-old woman, with a history of cesarean section 10 years ago, who came to Rumah Sakit Ibu dan Anak Anugerah, complained of not being able to urinate for a day and since a week ago there was always a spot of blood when urinating. From the anamnesis, there was difficulty in urinating for the last 2 months and she also felt lower abdominal pain, but it did not interfere with daily activities, and there was no menstrual pattern disturbance. This patient is a patient with secondary infertility with 1 son aged 10 years who was born by cesarean section due to a narrow pelvis and she did not use any contraception for 10 years ago because she wanted to get pregnant. Because there were no menstrual disorders, the patient first came to the internal medicine doctor because of complaints of hematuria, and then was referred to the gynecologist for further procedure.

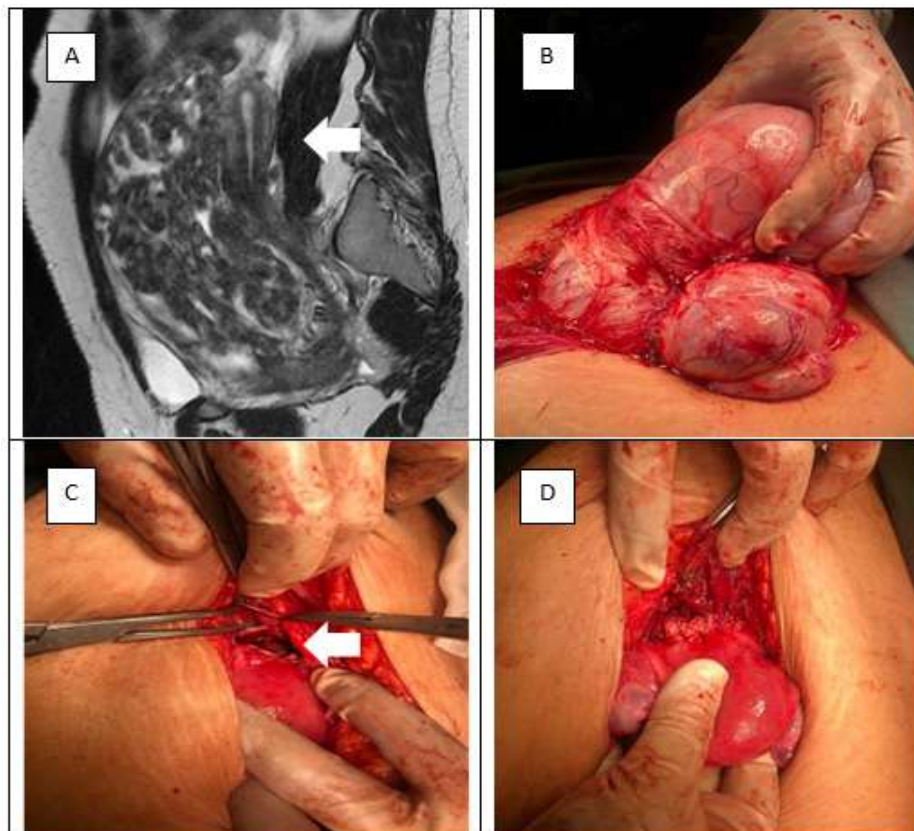
From the physical examination of the

abdomen, a lump with a hard consistency measuring 26-28 weeks was found in the lower abdomen which was difficult to move. From the gynecological examination (vaginal toucher) a soft cervix was found, in which smooth surface that did not bleed easily but a mass was palpable in the anterior fornix, a hard mass that was not mobile and was difficult to move, the uterus was difficult to feel from bimanual examination because the mass was pressing against the anterior wall of the urinary bladder.

From the MRI examination, a solid mass separated from the normal-sized uterus originating from the cervical area was obtained. A well-defined solid mass measuring 30 x 26 x 22 cm merged with the back wall of the urinary vesica and pushed the

right-left ureters causing mild hydronephrosis in both kidneys. Laboratory examination of blood, was still within normal limits except for the hemoglobin value which was 6.4 g% which was then planned for transfusion of 3 blood bags of PRC (pack red cells) type before surgery with premedication therapy in the form of 1 amp of corticosteroids and 1 amp of gluconas calcii after transfusion.

From all examinations, it was concluded that a cervical myoma was pressing against the urinary bladder and both inferior segment ureters in the patient who had a deep transperitoneal cesarean section accompanied by anemia and secondary infertility. After the patient received a transfusion, she underwent myomectomy surgery with DJ stent installation in both ureters with the risk



**Figure 1** A. MRI image of a Cervical Myoma (30 x 26 x 22 cm ) with a Normal Uterus (Arrow) before Surgery, B. Findings of Preoperative Myoma with Adhesions on the urinary bladder, C. Ruptured Vesica Urinaria or Perforation (arrow) after enucleation, D. Post Myomectomy Uterus after Bladder Repair.

of bladder injury and ureteral injury.

The first step of the laparotomy began with opening the previous cesarean section scar with general anesthesia was carried out after the patient understood and agreed with all the risks that might occur. After the patient was fully anesthetized, the urologist attempted to install DJ stent in both ureters but failed because the tumor mass was pressing the vesicourinaria and closing both ureteral openings; so, it was decided to perform a laparotomy and cystoscopy at the same time to install DJ stent by pushing the tumor mass towards the cranial and abdominal wall so that DJ stent could be attached to both ureters. After the two DJ stent were properly installed, the urinary bladder was set aside toward the caudal carefully while stopping the bleeding using electrosurgery (Erbe® VIO 3) and at the same time identifying the uterus which was in the posterior part of the cervical myoma mass originating from the cervix and attached to the lower uterine segment.

Cervical enucleation of myoma (myomectomy) was carried out in stages and simultaneously bleeding was controlled while paying attention to the opening of the ureter that had been attached to DJ stent and at the same time setting aside the vesica urinaria to the caudal. Cervical enucleation of myoma was carried out very gently to avoid injury to other organs; after an 80% enucleation period, it became difficult because the base of the cervical myoma had merged with the vesicaurinaria and was difficult to separate. So, together with our Urology colleagues, we carry out enucleation in stages until all of the cervical myoma was released even with the risk of injury to the vesico urinaria.

The cervical myoma mass managed to enucleate perfectly with the same size of dimensions obtained from the MRI examination, even though the injury in the form of a perforation of the vesicourinary was unavoidable. There was a perforation or tear in the upper part of the urinary bladder

which was elongated with irregular edges measuring 12 x 5 cm. After all the bleeding from the cervical wall and soft tissue around the cervical myoma was successfully stopped, the urologist ensured that the ureteral opening was not injured before doing the repairs to the torn vesicourinary wall by performing suture using two layers of PGA multifilament 2-0 thread and ensuring that there was no leakage with a methylene blue test through the catheter.

After making sure that there were no leaks due to closing the vesica urinaria, it was continued with continuous closure of the lower uterine segment using PGA multifilament 2-0 which then after all the equipment and gauze were completely counted, covering the abdomen layer by layer so the skin was closed by using PGA monofilament 4-0.

Postoperatively, the patient did not need to receive a transfusion because the hemoglobin level was 11.7 g% and the patient was allowed to go home 3 days after the operation, although the latest catheter might be removed 10 days after the operation.

The histopathological results of a mass measuring 30 x 26 x 22 cm corresponded to the cervical myoma accompanied by an infection in a small part of the cervix with an inflammatory process in the mucosa of the urinary vesica that adhered and merged with the mass.

## Discussion

Cervical myoma is a rare type of uterine myoma with a prevalence of 0.6% of all uterine myomas. The low prevalence of cervical myomas results in minimal literacy regarding the appropriate operative technique approach with minimal action complications. The operative technique approach is very dependent on the operator's experience and skill in determining whether this cervical myoma can be done with myomectomy or should be a hysterectomy with controlled

risk. Good knowledge of pelvic anatomy is absolutely necessary, especially in cervical myoma surgery.<sup>1,8</sup>

The size of the myoma will cause changes in the anatomy of the cervix, in which there is pressure on the bladder and or ureters so that the path and position will change. The posterior part of the myoma can be attached to the rectum, especially in patients with a history of endometriosis, or the anterior part of the cervical myoma is attached to the urinary bladder, especially in a former cesarean section surgery. The large size of cervical myoma also causes very limited access to the operating field. The surgery conducted on large cervical myoma is very risky if there is no good teamwork with colleagues in urology surgery and digestive surgery. In this case, there has been case discussion and consultation with surgical colleagues before the surgery begins, so that it can be carried out smoothly and complications can be handled properly.

Diagnosis of cervical myomas can generally be made by history, physical and supporting examination. Supporting examinations are generally carried out by ultrasound. However, other supporting examinations such as CT Scan and MRI are also important as the preparation of doing surgery in cervical myoma cases. Supportive examinations are important to rule out leiomyosarcoma, especially in cases of large myomas.<sup>9</sup> In this case, an MRI examination is performed to determine the size of the mass and assess its compression with the nearby organs. MRI can also assess myoma adhesions with the organs surrounding.<sup>10</sup>

The approach to the procedure of cervical myoma is hysterectomy; but in this case, the patient still wants to maintain fertility so a myomectomy is attempted instead, even though it is difficult and it has high complications. In this case, it is predicted that there will be difficulty in releasing the anterior cervical segment with the urinary

bladder and distortion/pressure on the ureter so that the anatomy of the ureter may change. Long-term collaboration with a urologist is needed so that even though there is a large tear in the urinary bladder (12x5 cm), it can be repaired immediately and there are no complications in the form of vesico-vaginal fistulas or vesico-cervical postoperatively.

## Conclusion

The procedure of cervical myoma might be varied for different patients. If the patient still need the reproduction organs, enucleation of the myoma is the right choice for this case. Large cervical enucleation of the myoma require both skill and accuracy because they carry a high risk of injury to the urinary bladder and ureter. Good teamwork with surgical colleagues can minimize the risk of surgery.

## References

1. Tiltman AJ. Leiomyomas of uterine cervix: A Study of frequency. *Int J GynaecolPathol.* 1998;17(3):231- 4.
2. Hoffman BL, Schorge JO, Schaffer JI, Halvorson LM, Bradshaw KD, Cunningham FG. *Williams gynecology.* 2nd ed. China: McGraw-Hill; 2012. p. 247-59.
3. Edmonds DK. *Dewhurst's textbook of obstetrics &gynaecology.* 7th ed. Massachusetts: Blacwell; 2007. p. 638-44.
4. Jeffcoate N. Tumors of corpus uteri. In: Bhatla N (ed). *Jeffcoate's Principles of Gynaecology,* 6th Ed. Delhi, Arnold Publication; 2001:466-497.
5. Kurjak A, Chervenak FA. *Textbook of ultrasound in obstetrics & gynecology.* New Delhi: Jaypee; 2010. p. 736-8.
6. Elshebiny YH, Ashebu SD, Hussien HM, El Naser AMA (2002) Leiomyoma of the urinary bladder: a case report. *East Afr*

Med J 79(10):557–559

7. Kurjak A, Chervenak FA. Textbook of ultrasound in obstetrics & gynecology. New Delhi: Jaypee; 2010. p. 736-8.
8. Federico F, Sara F, Gaetano V, Laura A, Fabio B, Esposito V, et al. Current Treatment Options for Cervical Leiomyomas: A Systematic Review of Literature. *Medicina* 2021, 57, 92.
9. Ayako S, Masato A, Chibo M, Kosuke M, Hisamitsu T, Kotani Y, et al. Differential diagnosis of uterine leiomyoma and uterine sarcoma using magnetic resonance images: a literature review. *Healthcare* 2019, 7(4), 158
10. Matthew LM, Mahan M, Michael S, Stefan G, Lawrence S, Pinar K, et al. Utility of magnetic resonance imaging in the evaluation of intraoperatively confirmed pelvic adhesions. *J Comput Assist Tomogr* 2015, 39(6):896-900.